

# Clinical outcomes of hip arthroscopy for older-aged patients

Yukizawa, Y<sup>1</sup>, Kobayashi, N<sup>1</sup>, Oishi, T<sup>1</sup>, Takagawa, S<sup>1</sup>,  
Tsuji, M<sup>1</sup>, Yutaka Inaba<sup>2</sup>

1:Yokohama City University Medical Center, Yokohama, Japan

2:Yokohama City University, Yokohama, Japan



COI

All authors have  
no disclosures  
to be reported.

# Purposes

To evaluate effects of hip arthroscopy for patients over 50 years old.

To identify factors leading to good or poor postoperative results.

# Patients

## Inclusion Criteria

- Patients underwent arthroscopic surgery between 2013 – 2019
- 50 years old and over
- FAI, OA, DDH

## Exclusion Criteria

- Past history of hip surgery
- Tumor, fracture, infection
- Extra-articular lesion

# Clinical Outcomes

- ✓ Patients Demographic Data
- ✓ Tönnis grade, Center-Edge angle
- ✓ Arthroscopic findings
- ✓ Questionnaires (MHHS, NAHS, pVAS)
- ✓ THA conversion rate

# Table 1 Patients Demographics and Radiographic Data

	Overall n=37	50s n=18, 49%	60s n=12, 32%	70s~ n=7, 19
Age	61±9	54±3	63±3	75±3
Sex, F/M	14/23	6/12	5/7	3/4
BMI	24±4	24±4	24±3	23±3
FAI	13, 35%	10, 56%	2, 17%	1, 14%
DDH	8, 22%	4, 22%	4, 33%	0, 0%
OA	16, 43%	4, 22%	6, 50%	6, 86%
CE angle	27±8	28±7	26±7	31±4
Tönnis 0	15, 41%	11, 61%	3, 25%	1, 14%
1	14, 38%	5, 28%	8, 67%	1, 14%
2	8, 21%	2, 11%	1, 8%	5, 72%
3	0	0	0	0

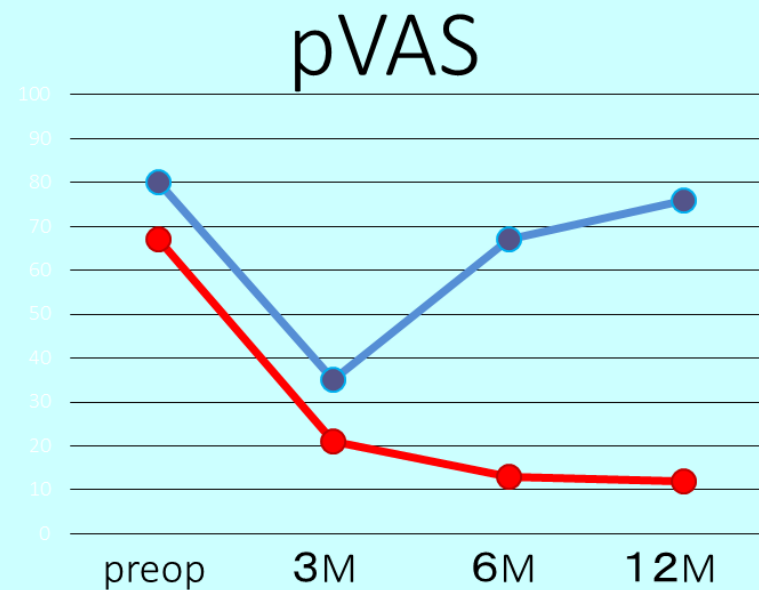
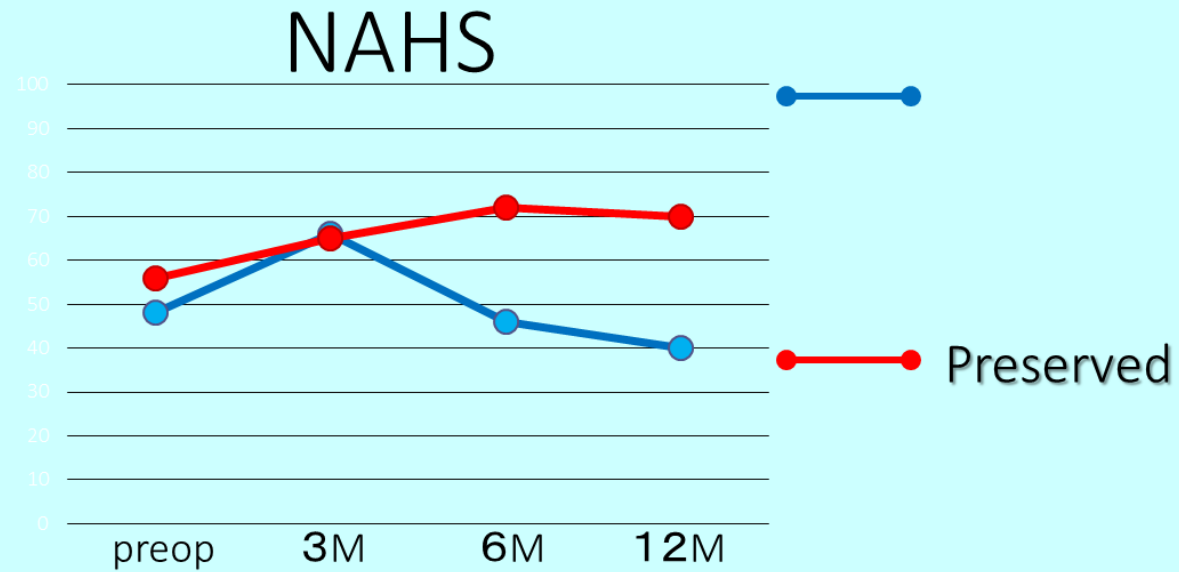
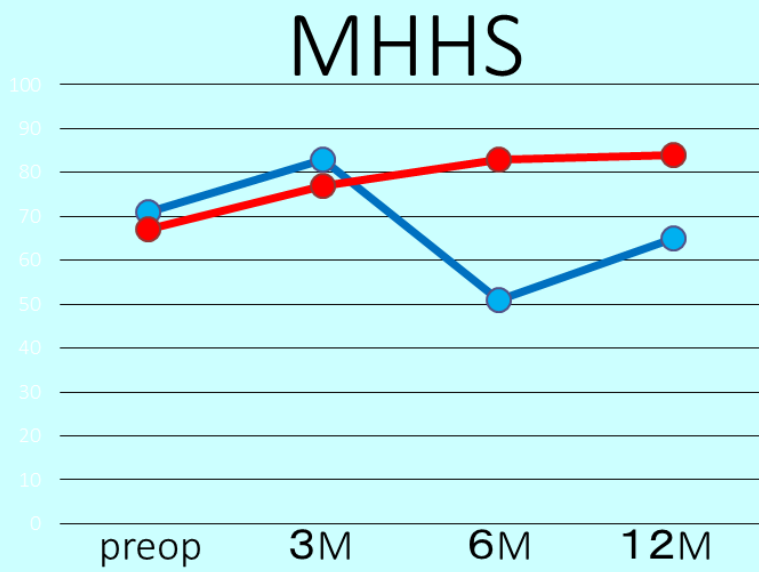
# Table 2 Arthroscopic Findings

	Overall	50s	60s	70s~
MAHORN I-II	24, 65%	12, 67%	9, 75%	3, 43%
III-V	13, 35%	6, 33%	3, 25%	4, 57%
ICRS(Acetabular)				
I-II	24, 65%	13, 72%	8, 67%	3, 43%
III-IV	13, 35%	5, 28%	4, 33%	4, 57%
ICRS(f. head)				
I-II	35, 95%	17, 94%	11, 92%	7, 100%
III-IV	2, 5%	1, 6%	1, 8%	0
Labrum repair	26, 70%	15, 83%	9, 75%	2, 29%
resection	11, 30%	3, 17%	3, 25%	5, 71%

	Overall	50s	60s	70s~
THA	5, 14%	1, 6%	3, 25%	1, 14%

Table 5 Uni- and Multi-variate and Multivariate analysis

Uni. analysis	Converted to THA n=5	Preserved n=32	p	Multi. analysis	Odds ratio	95% CI	p	
Age	67.2±3	60.8±11	0.001	Age	1.2	1.1 – 18.6	0.001	] Confound factors
MAHORN I-II	0, 0%	24, 75%	0.03	ICRS(acetabular)	3.4	1.7 – 7.8	0.001	
III-V	5, 100%	8, 25%		Labrum resection	5.5	1.3 – 11.3	0.025	
ICRS(acetabular)								
I-II	1, 20%	23, 72%	0.003					
III-IV	4, 80%	9, 28%						
Labrum repair	0, 0%	26, 81%	0.001					
resection	5, 100%	6, 19%						

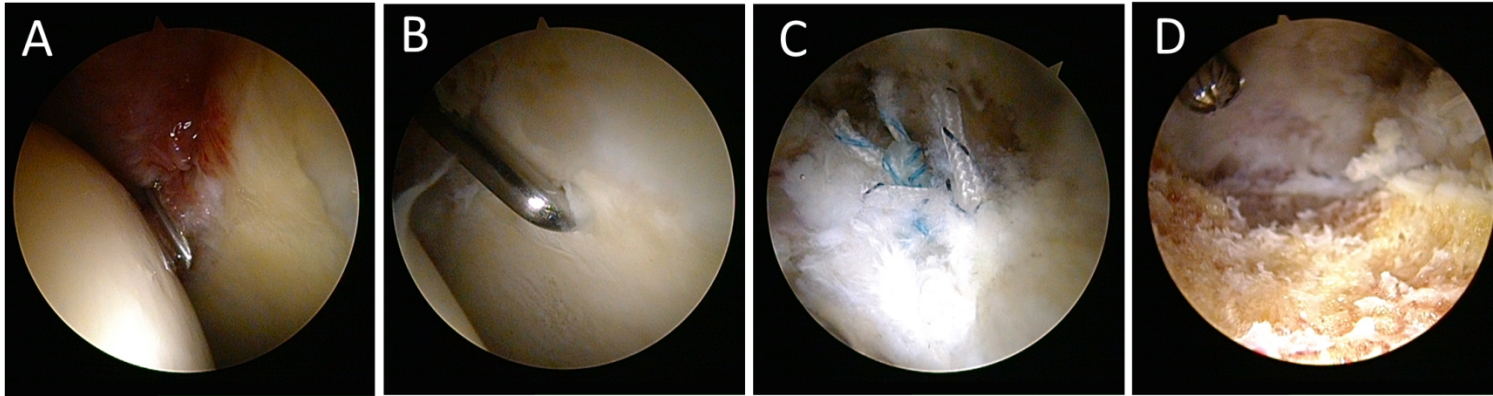


## Figure 1 Clinical Questionnaires

Both groups showed significant improvement in MHHS, NAHS, and pVAS at postoperative 3 months, and then hip preservable group could maintained higher scores until last follow-up. However, THA conversion group had re-worsened those scores at postoperative 6 and 12months.



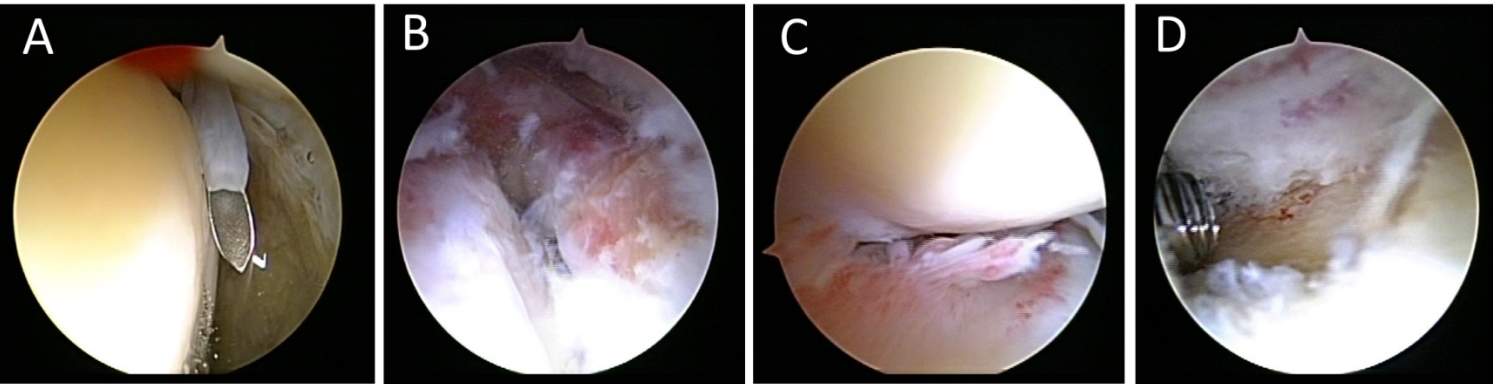
# 2 Cases Presentation



**Figure 2 A case of 74 year-old man**

A case of 74 year-old man complaining left hip pain. X-ray revealed FAI without evidence of OA (Tönnis grade 0). Arthroscopically, cartilage of both acetabular and the femoral head had not been damaged with the grade of 0-1 ICRS score(A, B). Labrum was completely torn and fixed by 2 anchors(C), and cam-plasty was performed(D).

Postoperatively, relief of the left hip pain was observed and maintained over 2 years.



**Figure 3 A case of 58 year-old woman**

A case of 58 year-old woman complaining left hip pain. X-ray revealed cam-type FAI with OA (Tönnis grade 1). Arthroscopically, cartilage of acetabular showed ICRS 3 damage and ICRS 1 on the femoral head(A). Anterolateral labrum was delaminated with acetabular cartilage extensively to posterior side(B, C). Labrum was partially debrided and cam-plasty was performed(D).

Postoperatively, OA progression could not be avoided and resulted in THA conversion in 1 year.

# Conclusion

Under evaluation of cartilage damage before intervention to the joints, hip arthroscopy could provide acceptable clinical outcomes even if patients were old.

